



CASE REPORT

Open Access

## Septic Arthritis of the Hip Joint Secondary to Haemophilus Influenza in Immunized Teenager: A Case Report

Sundus Al Habsi, Mazin Osama, Rahil Muzaffer, Humaid Al Farii\*

Sultan Qaboos University Hospital, Department of Surgery, Orthopedics Division, Oman.

### ABSTRACT

Septic arthritis is an infection to one joint or more that mainly happens after a hematogenous spread of an infection causing inflammation to the joint. Large joints such as hip and knee are more commonly affected, however, septic arthritis can happen in any other joints such as shoulders and ankles. *Staphylococcus aureus* is the most frequently isolated pathogen in this condition; however, other bacteria, viruses, fungi, and mycobacterium can also cause septic arthritis. Haemophilus influenzae type b (Hib) is the most common subtype of Haemophilus influenza and is primarily affecting children and those with compromised immune systems. Haemophilus influenza usually causes lower respiratory tract infections, including pneumonia. In addition, they can induce numerous other severe infections, such as bacteremia, empyema, meningitis, cellulitis, and septic arthritis.

The Hib conjugate vaccine has significantly reduced the incidence of Hib infections and is effective in protecting against capsular polysaccharide type b. the CDC recommends administering a conjugate Hib vaccine series beginning at age 2 months, or 6 weeks followed by boosters at age of 12 to 15 months. In this article, we are reporting a unique case of hip septic joint in a fully vaccinated teenager, and it is the first case reported in the literature to our knowledge.

### ARTICLE HISTORY

Received 06 May 2024  
Accepted 08 June 2024  
Published 14 June 2024

### KEYWORDS

Septic arthritis, Haemophilus influenza, Joint pain.

### Introduction

Septic arthritis is one of the few known orthopedic emergencies, Different clinical characteristics apply to this illness in adults, children, and neonates. The history and clinical presentation of a warm, swollen, painful joint with restricted range of motion are the main factors that lead to the diagnosis. When there is a clinical suspicion of septic arthritis, laboratory values and inflammatory markers from serum and joint fluid may be used to confirm diagnosis [1]. The identification of bacteria in synovial fluid by a positive culture of the pathogen is necessary for the final diagnosis of septic arthritis [2].

Treatment of septic joints starts right after taking the synovial samples by starting on antibiotics, gram-positive and gram-negative bacteria should be included in the first general antibiotic regimen [1]. The infected joint's culture results should be considered before determining the appropriate antibiotic regimen. Operative management entails debridement and thorough irrigation of all infected tissue following either an arthroscopy or an arthrotomy of the joint [1].

If septic joints left untreated, they could lead to joint destruction and even death due to septicemia. Septic joints will need to be emergently evacuated surgically [1-3].

Some bacteria are rare to cause septic joints, this case

report presents a rare case of a 15-year-old fully immunized young teenager who got right hip haemophilus influenza septic arthritis, aiming to enhance the understanding of this disease and its causes, the report discusses the clinical presentation, diagnostic evaluation, treatment approach, and patient outcome, emphasizing that septic joints secondary to haemophilus influenza type B can occur without proceeding severe respiratory infection in a vaccinated child or teenager.

### A Case Study

15 years-old previously healthy boy. Presented to the Emergency department with 3 days history of right hip joint pain. He presented on a wheelchair unable to bear weight. The hip joint was tender with restricted range of movement, no swelling, redness over the joint. Patient had upper respiratory tract infection (URTI) 4 days prior to hip pain with undocumented fever. He denied any history of trauma, no history of other joint involvement. He was up to date immunized, with no recent travel history, non-smoker, non-alcohol consumer or IV drug user. He had normal bowel and urine habits. Denied weight loss, night sweating or back pain. He did not have a history of unpasteurized milk consumption.

Laboratory workup of the patient showed Leukocytosis and highly elevated C-reactive protein (CRP). X-ray was unremarkable (Figure 1). Right hip ultrasound (US) was done and reported as

**Contact** Humaid Al Farii, Sultan Qaboos University Hospital, Department of Surgery, Orthopedics Division, Oman.

“there is evidence of right hip effusion evident as increased turbid/echogenic fluid in the anterior synovial recess on the right hip when compared to contralateral left hip. In addition, mild hypervascularity of the synovium which could represent synovitis in appropriate clinical sittings” (Figure 2).

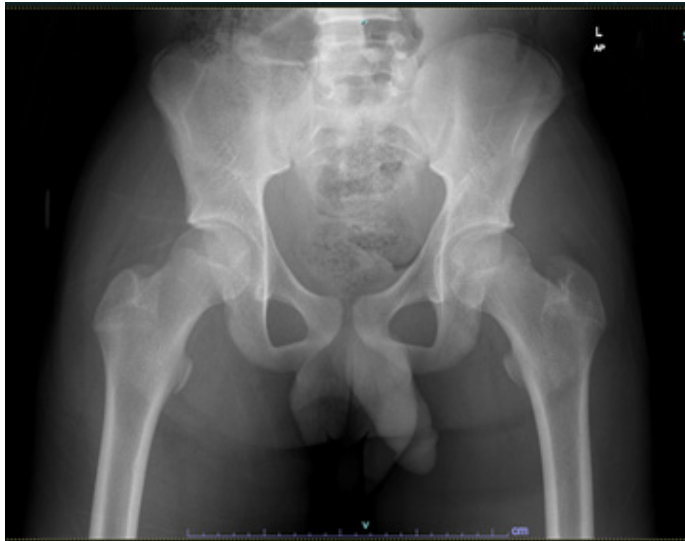

Figure 1: Pelvis X-ray of the patient.

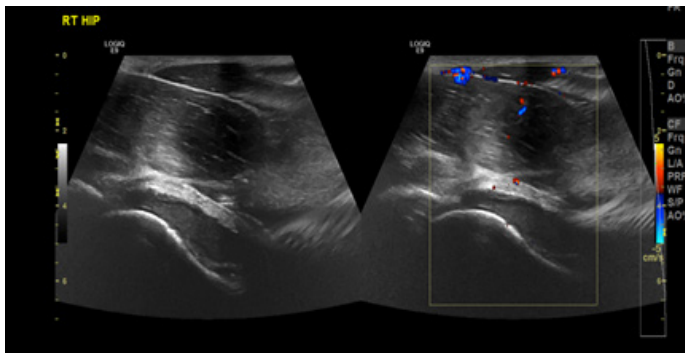


Figure 2: Right hip joint US of the patient.

Patient underwent surgical washout through arthrotomy using Smith-Peterson approach. Purulent fluid and unhealthy tissue were seen intra operative. Sample was collected for culture and histopathology, which turned out eventually to be *Haemophilus influenzae* type B.

Infectious disease team was involved and recommended IV Ceftriaxone for 2 weeks followed by oral Ciprofloxacin for 2 weeks and to immunize the child with HIB and DTP vaccine upon discharge. The patient did well post operatively in terms of pain, vital signs, and mobility. He left home after completing IV ceftriaxone regimen then seen at outpatient clinic at regular routine follow up.

## Discussion

The age above 60, recent bacteremia, diabetes, cancer, cirrhosis, renal disease, drug or alcohol abuse, history of corticosteroid injection, recent injury or surgery, prosthetic joint, and rheumatoid arthritis history are significant risk factors for developing septic arthritis [1]. Septic joints are mainly bacterial, it can be complicated or uncomplicated, the complicated type

is usually associated with osteomyelitis where the patients need antibiotics course post-surgical debridement for up to 4-6 weeks, while uncomplicated ones will grossly need antibiotics for a maximum of 4 weeks duration [2].

The gram-negative, opportunistic bacterium *Haemophilus influenzae* is most frequently detected in the upper respiratory tract of humans. Infection by these bacteria have decreased since vaccinations became available. However, an invasive infection, especially in the musculoskeletal system, can happen in the immunocompromised host [4,5].

*H. influenzae* type b (Hib) is the most common and well-known form, primarily affecting children and those with compromised immune systems. Other types like type A, E, and F are also isolated. Types C and D are identified very infrequently. Every serotype but especially type B is frequently the cause of lower respiratory tract infections like pneumonia. In addition, they can induce numerous other severe infections, including bacteremia, empyema, meningitis, cellulitis, and septic arthritis [4,5].

The Hib conjugate vaccine has significantly reduced the incidence of Hib infections and is effective in protecting against capsular polysaccharide type "B". Presently, most otitis media, sinusitis, and pneumonia cases in patients who have already received the vaccine are caused by non-encapsulated *H. influenzae*, also known as non-typeable *H. influenzae* (NTHi). The disease is spread by close contact or inhalation of respiratory secretion droplets from infected people [4,5].

Septic arthritis must be treated with antibiotics as soon as possible, and the pathogen causing the illness must be identified to be targeted with antibiotics. In the past, the primary pathogens of the disease were thought to be *Staphylococcus aureus*, *Streptococcus pyogenes*, *Streptococcus pneumoniae*, and *Haemophilus influenzae* type B. However, the last twenty years have seen a significant shift in our understanding of the etiology of infectious arthritis due to the introduction of vaccination programs against pneumococci and *H. influenzae* type b, as well as the application of better detection techniques [6].

Given this information about *H. influenzae*, it become very obvious that septic joint can still happen despite the child has been vaccinated. We present a rare case of a young teenager who got diagnosed with *H. influenzae* septic hip, underwent surgical arthrotomy and washout of the joint along with antibiotics course of 4 weeks.

## Conclusions

Although it is rare for *H. influenzae* bacterium to cause septic arthritis in an immunized child, we are reporting its existence to make the awareness among health care providers. Septic arthritis should always be suspected in any patient with fever, painful range of movement and high inflammatory markers. The ideal treatment would include surgical washout as early as possible and appropriate antibiotics with adequate duration.

## References

1. Elsisy JG, Liu JN, Wilton PJ, Nwachuku I, Gowd AK, et al. Bacterial Septic Arthritis of the Adult Native Knee Joint: A Review. *JBJS Rev.* 2020; 8(1): e0059.

2. García-Arias M, Balsa A, Mola EM. Septic arthritis. *Best Pract Res Clin Rheumatol.* 2011; 25(3): 407-421.
3. Ross JJ. Septic Arthritis of Native Joints. *Infect Dis Clin North Am.* 2017; 31(2): 203-218.
4. Faruqi T, Green A, McCall DP, Caid M, Smith LC. Polyarticular Haemophilus Influenza Septic Arthritis in an HIV Patient. *Cureus.* 2021; 13(12): e20160.
5. Khattak ZE, Anjum F. Haemophilus influenzae Infection. *StatPearls Publishing.* 2023.
6. Yagupsky P. Changing aetiology of paediatric septic arthritis. *J Paediatr Child Health.* 2021; 57(10): 1560-1563.